

Evaluation and Management of Peripheral Vascular Injury. Part 1.

Western Trauma Association/Critical Decisions in Trauma

David V. Feliciano, MD, Frederick A. Moore, MD, Ernest E. Moore, MD, Michael A. West, MD, PhD,
James W. Davis, MD, Christine S. Cocanour, MD, Rosemary A. Kozar, MD, PhD,
and Robert C. McIntyre, Jr., MD

(*J Trauma*. 2011;70: 1551–1556)

This is a position article from members of the Western Trauma Association (WTA). Because there are no prospective randomized trials on the evaluation and management of peripheral vascular trauma, the algorithm (Fig. 1) is based on the expert opinion of WTA members and published observational studies. It may not be applicable at all hospitals caring for injured patients. The algorithm contains letters that correspond to lettered text that is intentionally concise. This Part I algorithm emphasizes evaluation, diagnosis, and need for operation versus a therapeutic procedure performed in interventional radiology, while a Part II algorithm (2011) will focus on operative techniques.

Peripheral vascular injuries defined as axillobrachial and branches in the upper extremity and femoropopliteal and branches in the lower extremity account for 40% to 75% of all vascular injuries treated in civilian trauma centers.^{1–4} With the exception of the axillary artery, the long tracks of named arteries and veins in the extremities make them particularly

susceptible to either penetrating or blunt trauma. This fact coupled with the smaller diameter of many of these vessels (as compared with those in the thorax or abdomen) and the ability of the patient and others to control external hemorrhage with compression contribute to a low incidence of death in the field.

HISTORIC PERSPECTIVE

Urgent repair of an injury to the brachial artery was first performed by Hallowell on June 13, 1759, at the site of a “blood letting.”⁵ After a 145-year delay, techniques of arterial repair were developed by Nobel Prize winner (1912) Alexis Carrel and Charles C. Guthrie at the University of Chicago from 1904 to 1906.⁶ Operative repairs of arterial injuries in the early part of the 20th century, most performed in a delayed fashion after wounding, were reported by V. Soubbotitch in the Balkan Wars, George H. Makins in World War I, and R. Weglowski during the Polish-Russian War of 1920.^{7–9} Less than 150 arterial repairs in American military personnel during World War II were reported by DeBakey and Simeone¹⁰ in their classic review published in 1946. This small number was a reflection of the magnitude of military wounds, delays in medical care, lack of antibiotics, and the significant risk of late infection in injured soft tissues of the extremities. Vascular repairs were performed frequently in the later stages of the Korean War and routinely throughout the Vietnam War.^{11,12} Over the past 50 years, urban trauma centers in the United States have treated an extraordinary number of patients with arterial injuries from gunshot wounds.³

ETIOLOGY

In urban trauma centers in the United States, peripheral vascular injuries are most commonly (75–80%) caused by penetrating trauma.¹³ Approximately 50% of these penetrating injuries are caused by missiles from handguns with low muzzle velocity and low kinetic energy (<1,000 ft lbs).¹³ Stab wounds account for 30% of these penetrating peripheral vascular injuries in the United States, but are a much more common cause in countries in which firearms are more difficult to obtain.¹⁴ Shotgun wounds cause peripheral vascular injuries only 5% of the time. Peripheral vascular injuries from blunt trauma to the extremities such as fractures, dislocations, crush injuries, and traction account for only 5% to 25% of those being treated.^{15,16}

Submitted for publication July 26, 2010.

Accepted for publication March 18, 2011.

Copyright © 2011 by Lippincott Williams & Wilkins

From the University of Florida (F.A.M.), Gainesville, Florida; Denver Health Medical Center/University of Colorado (E.E.M.), Denver, Colorado; San Francisco General Hospital/University of California (M.A.W.), San Francisco, San Francisco, California; University of California (J.W.D.), Fresno, Fresno, California; University of California (C.S.C.), Davis Medical Center, Sacramento, California; University of Texas Health Science Center (R.A.K.), Houston, Texas; University of Colorado (R.C.M.), Denver, Colorado; and Grady Memorial Hospital/Emory University School of Medicine (D.V.F.), Atlanta, Georgia.

Presented at the 40th Annual Meeting, Western Trauma Association, February 28 to March 7, 2010, Telluride, Colorado.

The Western Trauma Association (WTA) develops algorithms to provide guidance and recommendations for particular practice areas, but does not establish the standard of care. The WTA develops algorithms based on the evidence available in the literature and the expert opinion of the task force in the recent timeframe of the publication. The WTA considers use of the algorithm to be voluntary. The ultimate determination regarding its application is to be made by the treating physician and health-care professionals with full consideration of the individual patient's clinical status as well as available institutional resources and is not intended to take the place of health-care providers' judgment in diagnosing and treating particular patients.

Address for reprints: David V. Feliciano, MD, Grady Memorial Hospital, 69 Jesse Hill Jr. Drive, SE, #304, Atlanta, GA 30303; email: dfelici@emory.edu.

DOI: 10.1097/TA.0b013e31821b5b5d

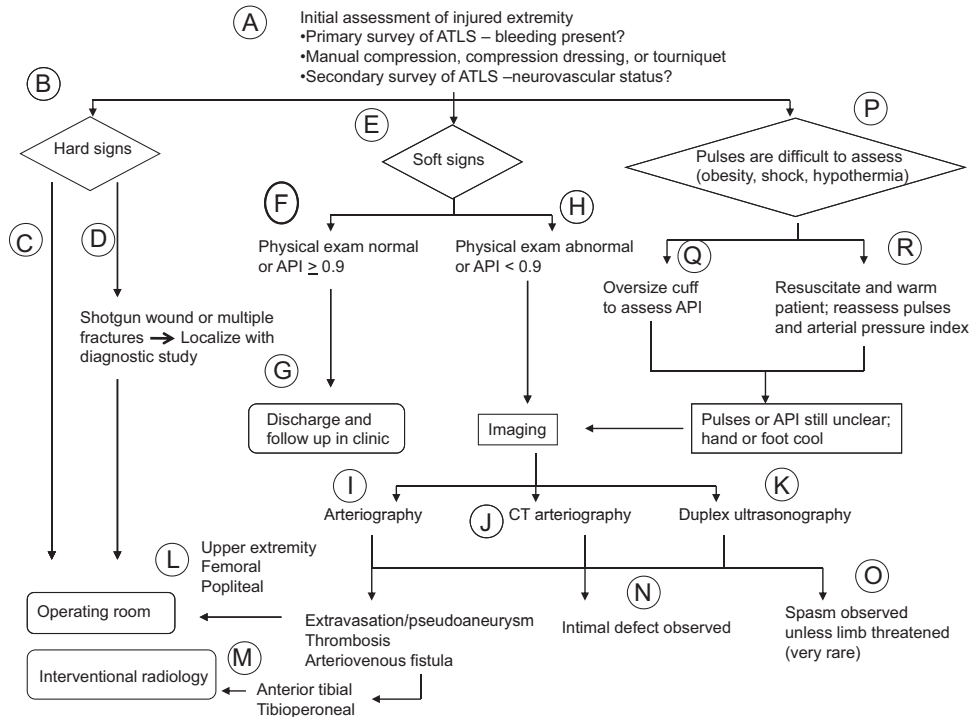


Figure 1. Algorithm for evaluation of patient with possible peripheral vascular injury.

LOCATION

In civilian series of arterial injuries, the extremities are the most common location.^{3,13} Among arteries in the extremities, 50% to 60% of injuries occur in the femoral or popliteal arteries and 30% in the brachial artery.^{3,13}

TYPES OF VASCULAR TRAUMA

The five recognized types of vascular injuries are as follows: (1) intimal injuries (flaps, disruptions, or subintimal/intramural hematomas); (2) complete wall defects with pseudoaneurysms or hemorrhage; (3) complete transections with hemorrhage or occlusion; (4) arteriovenous fistulas; and (5) spasm.¹⁷ Intimal defects and subintimal hematomas with possible secondary occlusion are most commonly associated with blunt trauma, while wall defects, complete transections, and arteriovenous fistulas usually occur with penetrating trauma. Spasm can occur after either blunt or penetrating trauma to an extremity and is more common in young patients. When there is an injury to the intima or intima/media and dilatation of an artery occurs, this is a *traumatic true aneurysm* with no extravasation of blood outside the lumen of the artery. A full-thickness defect in the wall of an artery with extravasation of blood outside the lumen is an acute pulsatile hematoma immediately after injury and a *traumatic false aneurysm* when the surrounding tissues encapsulate the blood. Traumatic aneurysms after venous injuries are extraordinarily rare, and traumatic wall defects in many veins seem to heal if local tissue pressure prevents significant extravasation of blood.

RISK TO THE PATIENT

The primary risk to a patient with a significant peripheral vascular injury is loss of life from exsanguination or the development of multiple organ failure from prehospital near-exsanguination.¹⁸ As manual compression or the application of a pressure dressing and elevation of the extremity can almost always control arterial bleeding from an extremity in the field, loss of life should be infrequent in an urban setting. The successful use of tourniquets in Operation Enduring Freedom (Afghanistan) and Operation Iraqi Freedom by American military forces, however, will almost surely lead to an increased use by civilian emergency medical services in the future.^{19,20} A secondary risk is loss of the extremity distal to the peripheral arterial injury. This is most commonly due to a delay in diagnosis and/or revascularization, thrombosis of an arterial or venous repair, or the magnitude of associated injuries to soft tissue, bones, or nerves (i.e., Gustilo III C open fracture or close-range shotgun wound). In large series of penetrating wounds to vessels in the extremities in an urban environment, only 2% to 4% of patients undergo immediate amputation and 1.5% to 2% delayed amputation.²¹ With blunt vascular injuries to the extremities, particularly those associated with open fractures (i.e., Gustilo III C), amputation rates continue to be at least 10% to 20%.^{16,22}

ANNOTATED TEXT FOR FIGURE 1

A. Bleeding from an injured extremity affects “Circulation” during the Primary Survey of Advanced Trauma Life Support and should be managed with direct pressure or a

compressive dressing and ongoing resuscitation. In the absence of bleeding, the injured extremity is assessed during the Secondary Survey of Advanced Trauma Life Support. The assessment for a possible arterial injury is dependent on the presence of normal versus diminished or absent pulses on physical examination or use of the Doppler device. Therefore, a fracture or dislocation of a joint in the injured extremity should be realigned or relocated, respectively, should first palpation of distal pulses during the Secondary Survey document a difference between the injured and a contralateral uninjured extremity in the hemodynamically stable patient.^{16,17}

- B. "Hard" or overt signs of an arterial injury in an extremity are as follows: (1) external bleeding; (2) a rapidly expanding hematoma; (3) any of the classical signs of arterial occlusion (pulselessness, pallor, paresthesias, pain, paralysis = 5 "P"s); and (4) a palpable thrill/audible bruit.^{17,23} Immediate operation on the injured extremity is appropriate in the patient without other life-threatening injuries (see "C" and "D" below). In the patient with an intracranial hematoma with midline shift of the brain, hemorrhage in the chest, abdomen or pelvis, gastrointestinal contamination in the abdomen, or injuries to vessels in two extremities, two operative teams, are appropriate. One team should manage the life-threatening injury elsewhere, while the second team should control peripheral arterial (or venous) hemorrhage or correct arterial occlusion and insert a temporary intraluminal shunt in the injured artery or vein.²⁴
- C. Patients with external bleeding or a rapidly expanding hematoma anywhere in an injured extremity undergo immediate operation. Other patients with presumed occlusion of a major named artery (limb is threatened) or clinical signs of an arteriovenous fistula (thrill/bruit) in the upper extremity, thigh (excluding the profunda femoris artery), or proximal to the anterior tibial artery and tibioperoneal bifurcation in the leg should undergo immediate operation, as well.^{13,17} The remaining hemodynamically stable patients with a presumed wall defect or occlusion of a named artery (i.e., dorsalis pedis pulse is absent, but foot is clearly well perfused) or clinical signs of an arteriovenous fistula in the distal two third of the leg should undergo diagnostic imaging (see "I," "J," and "K") and possible therapeutic embolization versus non-operative management (see "M").²⁵
- D. If a hard sign of arterial injury is present, but localization of the defect is necessary (i.e., shotgun wound or multiple fractures), two rapid options are available. Either a preliminary surgeon-performed arteriogram is performed in the emergency center or operating room or a duplex ultrasonography study is performed by an experienced vascular surgeon or registered vascular technologist if it can be done in a timely fashion.^{26–28}
- E. "Soft" signs of an arterial injury in an extremity are as follows: (1) a history of arterial bleeding at the scene or in transit; (2) proximity of a penetrating wound or blunt injury to an artery; (3) a small nonpulsatile hematoma over an artery; and (4) a neurologic deficit originating in

a nerve adjacent to a named artery.^{17,23} The incidence of arterial injuries in such patients ranges from 3% to 25%, depending on which soft sign or combination of soft signs is present.^{29–32} A physical examination that documents pulses at the wrist or ankle equal to those in the contralateral uninjured extremity is excellent evidence that no arterial injury or a limited arterial injury (i.e., intimal injury) is present.^{32–34} In addition to a comprehensive physical examination, one of the following should be performed: (1) Ankle or Brachial/Brachial Index (ABI or BBI = systolic blood pressure in extremity distal to area of injury/systolic blood pressure in brachial artery of uninjured upper extremity); (2) Arterial Pressure Index (API = Doppler arterial pressure distal to injury/Doppler arterial pressure in uninjured upper extremity).^{35–38} Using a cutoff of ≥ 0.9 to rule out the need for diagnostic imaging studies, the sensitivity and specificity as compared with clinical outcome have been reported to be $>95\%$.^{36,38} In older patients with a greater incidence of preexisting peripheral arterial occlusive disease, the ABI and/or API may not be as accurate as in younger injured patients. For this reason, some trauma centers will use a difference in ABI or API of ≥ 0.1 when comparing an injured extremity with an uninjured extremity as an indication for a diagnostic imaging study.

- F. A patient with pulses at the wrist or ankle equal to those in the contralateral uninjured extremity or with an API ≥ 0.9 in the injured extremity is discharged from the emergency room. This would include patients who have had reduction of posterior dislocation of the knee.³⁴ Follow-up in these patients is described in "G."
- G. As 1% to 4% of these patients, primarily those with penetrating wounds, eventually come to operation as the original undetected injury (i.e., small pseudoaneurysm) progresses rather than heals, compulsive follow-up in the outpatient clinic is mandatory.^{29,32,33,39,40} This would include a comprehensive physical examination in addition to a noninvasive Doppler examination. Any abnormality in these evaluations would mandate the performance of a duplex ultrasound and/or standard or computed tomographic (CT) arteriogram.
- H. A patient with diminished pulses at the wrist or ankle as compared with those in the contralateral uninjured extremity or with an API < 0.9 in an injured extremity should undergo an imaging study to document the presence and location of a likely arterial injury.^{36–38,41} The choice of an imaging study varies depending on local expertise, but most data are available on arteriography, CT arteriography, or a duplex ultrasonography study.
- I. Standard arteriography options include conventional film, digital subtraction after intra-arterial or intravenous injection of a contrast agent, or surgeon-performed "one-or two-shot" studies.^{26,42–44} Digital subtraction arteriography has replaced conventional film arteriography in most centers, because it decreases the time of examination, amount of contrast material, discomfort of the patient, and costs of films.^{42,43} A mobile digital subtraction arteriography unit can even be used in the trauma resuscitation

room when surgeon-angiographers are available.⁴⁵ If computed tomographic angiography (CTA) (see below) is not available, surgeon-performed arteriography can be performed in the emergency center using conventional films and one or two intra-arterial injections of 25 mL to 50 mL of meglumine diatrizoate dye. In the operating room, surgeon-performed arteriography can be performed under fluoroscopy or with the use of conventional films. Surgeon-performed percutaneous intra-arterial injection studies in injured patients have a complication rate of 1% to 4% and sensitivity/specificity greater than 95%.^{44,46} As certain contrast agents cause renal toxicity, adequate fluid resuscitation is mandatory before all the studies described.

- J. Multidetector row helical CTA has the advantages of using only intravenous contrast, being readily available in almost all American hospitals evaluating injured patients, and having an accuracy comparable with that of conventional arteriography.^{47–50} As it can be readily performed at the same time as other CT evaluations, it is cost effective as well.⁵⁰ Since conventional arteriography of the extremities has increased risks in children, CTA would be of particular benefit in this group. Limitations in diagnostic quality may occur when metallic fragments or bullets cause CT artifacts, but this was not a significant problem in a recent series from a military hospital.⁵¹ Also, no therapeutic interventions can be performed during the study. Finally, the increased contrast load needed may be detrimental in a patient with preexisting renal insufficiency or a concurrent renal injury.
- K. Duplex ultrasonography is a combination of real-time B (brightness)-mode imaging and pulsed Doppler velocimetry that demonstrates anatomic relationships and flow.⁵² Flow to and from the point of the Doppler examination can be represented on a color scale as well. Numerous clinical studies have documented the excellent accuracy of duplex ultrasonography in assessing arterial injuries. While sensitivity has ranged from 50% to 100%, specificity and accuracy have consistently exceeded 95%.^{28,53–55} Disadvantages of this diagnostic approach include the initial cost of the equipment, need for 24-hour availability of a registered vascular technologist or experienced vascular surgeon trained in duplex, and concerns about studies in the axilla and bifurcated arteries in older studies.⁵⁶
- L. An imaging study that documents the presence of extravasation, an acute pulsatile hematoma or early pseudoaneurysm, occlusion, or an arteriovenous fistula of a major named artery mandates an emergent operation, depending on location. As in “C,” this would be appropriate in major named arterial injuries in the upper extremity, thigh excluding the profunda femoris artery, or proximal to the anterior tibial artery and tibioperoneal bifurcation in the leg.
- M. In the hemodynamically stable patient, an imaging study that documents a wall defect with extravasation, occlusion, or the presence of an arteriovenous fistula in the profunda femoris, anterior tibial, posterior tibial, or peroneal arteries is followed by observation (occlusion) or therapeutic embolization (extravasation, arteriovenous fistula). A repeat arteriogram or duplex ultrasonography is performed 3 days to 5 days later in patients with occlusion to rule out the presence of an acute pulsatile hematoma or pseudoaneurysm developing from distal backflow.
- N. An intimal defect documented on an imaging study is expected to heal 87% to 95% of the time without operation.^{33,57} In the absence of injuries to the brain, solid viscera of the abdomen, or extensive soft tissue wounds, some centers will initiate prophylaxis against thrombosis with heparin or aspirin during the period of observation. A patient who maintains flow to the hand or foot and has no clinical findings suggestive of a developing pseudoaneurysm or arteriovenous fistula is discharged home at the discretion of the attending surgeon. The patient is then reexamined in the outpatient clinic (see G). Patients who develop abrupt changes in perfusion to the hand or foot or signs of a new pseudoaneurysm or arteriovenous fistula undergo urgent diagnostic imaging.
- O. Spasm of a peripheral artery in an injured extremity in a young patient is a common finding on imaging, whether or not the artery has been injured. If distal flow to the hand or foot is intact, observation with warming of the affected part of the extremity is appropriate. Before arterial spasm is thought to be the cause of an ischemic hand or foot, distal in situ thrombosis, distal embolism, or the presence of an advanced compartment syndrome must be ruled out.⁵⁸ This mandates a repeat arteriographic study or emergent measurement of compartment pressures in both the proximal and distal limb. Severe limb-threatening arterial spasm has been treated with a proximal intra-arterial bolus injection of papaverine 60 mg followed by an infusion of 30 mg/h to 60 mg/h in the past.⁵⁹ Another option used on rare occasions has been a proximal intra-arterial infusion of a solution of 1,000 mL normal saline; 1,000 units heparin; and 500 mg tolazoline at a rate of 30 mL/h to 60 mL/h.^{60,61} Currently used vasodilators in angiography suites include intra-arterial nitroglycerin (50–100 mg) or nifedipine (10 mg per os or sublingual).
- P. It is difficult to assess pulses at the wrist or ankle or measure an ABI, a BBI, or an API in a patient who is obese or when the patient is in shock or is hypothermic.
- Q. An oversized blood pressure cuff appropriate to the patient’s size should be used to assess an arterial pressure index in the obese patient.
- R. A patient in shock or one who is hypothermic should be resuscitated in the usual fashion and treated with all the standard warming maneuvers. Palpation of distal pulses and/or another attempt at measuring an arterial pressure index should then be performed.
- S. If a comparison (between the injured and the contralateral uninjured extremity) of pulses at the wrists or ankles or an ABI, a BBI, or an API cannot be completed in the now hemodynamically stable patient, a diagnostic imaging study should be performed on the injured extremity. This would be necessary, as well, if the hand or foot of the injured extremity seems to be cooler or have slower

capillary refill at the fingernails/toenails as compared with the contralateral uninjured extremity.

REFERENCES

- Perry MO, Thal ER, Shires GT. Management of arterial injuries. *Ann Surg*. 1971;173:403–408.
- Hardy JD, Raju S, Neely WA, Berry DW. Aortic and other arterial injuries. *Ann Surg*. 1975;181:640–653.
- Mattox KL, Feliciano DV, Burch J, Beall AC Jr, Jordan GL Jr, De Bakey ME. Five thousand seven hundred sixty cardiovascular injuries in 4459 patients. Epidemiologic evolution 1958 to 1987. *Ann Surg*. 1989;209:698–707.
- Oller DW, Rutledge R, Clancy T, et al. Vascular injuries in a rural state: a review of 978 patients from a state trauma registry. *J Trauma*. 1992;32:740–746.
- Hallowell. Extract of a letter from Mr. Lambert, surgeon at Newcastle upon Tyne, to Dr. Hunter, giving an account of new method of treating an aneurysm. *Med Obser Inq*. 1762;30:360. (Cited by Rich NM. Historical and military aspects of vascular trauma (with lifetime reflections of Dr. Norman Rich). In: Rich NR, Mattox KL, Hirshberg A, eds. *Vascular Trauma*. 2nd ed. Philadelphia, PA: Elsevier Saunders; 2004: 3–72.
- Dente CJ, Feliciano DV. Alexis Carrel (1873–1944). Nobel Laureate, 1912. *Arch Surg*. 2005;140:609–610.
- Soubbotitch V. Military experiences of traumatic aneurysms. *Lancet*. 1913;2:720–721.
- Makins GH. *On Gunshot Injuries to the Blood Vessels. Founded on Experience Gained in France During the Great War, 1914–1918*. Bristol, England: John Wright and Sons Ltd; 1919.
- Noszczyk W, Witkowski M, Weglowski R. The Zamosc period in the work of Romuald Weglowski. *Polski Przegl Chir*. 1985;57:440–445.
- DeBakey ME, Simeone FA. Battle injuries of the arteries in World War II. An analysis of 2,471 cases. *Ann Surg*. 1946;123:534–579.
- Hughes CW. Arterial repair during the Korean War. *Ann Surg*. 1958;147:555–561.
- Rich NM, Baugh JH, Hughes CW. Acute arterial injuries in Vietnam: 1000 cases. *J Trauma*. 1970;10:359–369.
- Frykberg ER, Schinco MA. Peripheral vascular injury. In: Feliciano DV, Mattox KL, Moore EE, eds. *Trauma*. 6th ed. New York, NY: McGraw-Hill; 2008:941–971.
- Robbs JV, Baker LW. Cardiovascular trauma. *Curr Prob Surg*. 1988;21:1–87.
- Cooper C, Rodriguez A, Omert L. Blunt vascular trauma. *Curr Prob Surg*. 1996;29:281–357.
- Rozycki GS, Tremblay LN, Feliciano DV, McClelland WB. Blunt vascular trauma in the extremity: diagnosis, management, and outcome. *J Trauma*. 2003;55:814–824.
- Feliciano DV. Evaluation and treatment of vascular injuries. In: Browner BD, Jupiter JB, Levine AM, Trafton PG, Krettek C, eds. *Skeletal Trauma. Basic Science, Management, and Reconstruction*. Philadelphia, PA: Saunders Elsevier; 2009:323–340.
- Dorlac WC, DeBakey ME, Holcomb JB, et al. Mortality from isolated civilian penetrating extremity injury. *J Trauma*. 2005;59:217–222.
- Beekley AC, Sebesta JA, Blackburne LH, et al. Prehospital tourniquet use in Operation Iraqi Freedom: effect on hemorrhage control and outcomes. *J Trauma*. 2008;64:S28–S37.
- Swan KG Jr, Wright DS, Barbagiovanni SS, Swan BC, Swan KG. Tourniquets revisited. *J Trauma*. 2009;66:672–675.
- Feliciano DV, Herskowitz K, O’Gorman RB, et al. Management of vascular injuries in the lower extremities. *J Trauma*. 1988;28:319–328.
- Atterberry LR, Dennis JW, Russo-Alesi F, Menawat SS, Lenz BJ, Frykberg ER. Changing patterns of arterial injuries associated with fractures and dislocations. *J Am Coll Surg*. 1996;183:377–383.
- Synder WH, Thal ER, Bridges RA, Gerlock AJ, Perry MO, Fry WJ. The validity of normal arteriography in penetrating trauma. *Arch Surg*. 1978;113:424–428.
- Subramanian A, Vercruyse G, Dente C, Wyrzykowski A, King E, Feliciano DV. A decade’s experience with temporary intravascular shunts at a civilian level I trauma center. *J Trauma*. 2008;65:316–326.
- McNeese S, Finck E, Yellin AE. Definitive treatment of selected vascular injuries and post-traumatic arteriovenous fistulas by arteriographic embolization. *Am J Surg*. 1980;140:252–259.
- O’Gorman RB, Feliciano DV. Arteriography performed in the emergency center. *Am J Surg*. 1986;152:323–325.
- Callcut RA, Acher CW, Hoch J, Tefera G, Turnipseed W, Mell MW. Impact of intraoperative arteriography on limb salvage for traumatic popliteal artery injury. *J Trauma*. 2009;67:252–258.
- Knudson MM, Lewis FR, Atkinson K, Neuhaus A. The role of duplex ultrasound arterial imaging in patients with penetrating extremity trauma. *Arch Surg*. 1993;128:1033–1038.
- Reid JDS, Weigelt JA, Thal ER, Francis H III. Assessment of proximity of a wound to major vascular structures as an indication for arteriography. *Arch Surg*. 1988;123:942–946.
- Frykberg ER, Vines FS, Alexander RH. The natural history of clinically occult arterial injuries: a prospective evaluation. *J Trauma*. 1989;29:577–583.
- Dennis JW, Frykberg ER, Crump JM, Vines FS, Alexander RH. New perspectives on the management of penetrating trauma in proximity to major limb arteries. *J Vasc Surg*. 1990;11:84–93.
- Frykberg ER, Dennis JW, Bishop K, Laneve L, Alexander RH. The reliability of physical examination in the evaluation of penetrating extremity trauma for vascular injury: results at one year. *J Trauma*. 1991;31:502–511.
- Dennis JW, Frykberg ER, Veldenz HC, Huffman S, Menawat SS. Validation of nonoperative management of occult vascular injuries and accuracy of physical examination alone in penetrating extremity trauma: 5-to-10-year follow-up. *J Trauma*. 1998;44:243–253.
- Miranda FE, Dennis JW, Veldenz HC, Dovgan PS, Frykberg ER. Confirmation of the safety and accuracy of physical examination in the evaluation of knee dislocation for popliteal artery injury: a prospective study. *J Trauma*. 2002;52:247–252.
- Johansen K, Lynch K, Paun M, Copass M. Non-invasive vascular tests reliably exclude occult arterial trauma in injured extremities. *J Trauma*. 1991;31:515–522.
- Lynch K, Johansen K. Can Doppler pressure measurement replace “exclusion” arteriography in the diagnosis of occult extremity arterial trauma? *Ann Surg*. 1991;214:737–741.
- Nassoura ZE, Ivatury RR, Simon RJ, Jabbour N, Vinzons A, Stahl W. A reassessment of Doppler pressure indices in the detection of arterial lesions in proximity penetrating trauma to the extremities: a prospective study. *Am J Emerg Med*. 1996;14:151–156.
- Sadjadi J, Cureton EL, Dozier KC, Kwan RO, Victorino GP. Expedited treatment of lower extremity gunshot wounds. *J Am Coll Surg*. 2009;209:740–745.
- Feliciano DV, Cruse PA, Burch JM, Bitondo CG. Delayed diagnosis of arterial injuries. *Am J Surg*. 1987;154:579–584.
- Richardson JD, Vitale GC, Flint LM Jr. Penetrating arterial trauma. Analysis of missed vascular injuries. *Arch Surg*. 1987;122:678–683.
- Schwartz MR, Weaver FA, Bauer M, Siegel A, Yellin AE. Refining the indications for arteriography in penetrating extremity trauma: a prospective analysis. *J Vasc Surg*. 1993;17:116–124.
- Goodman PC, Jeffrey RB Jr, Brant-Zawadski M. Digital subtraction angiography in extremity trauma. *Radiology*. 1984;153:61–64.
- Sibbit RR, Palmaz JC, Garcia F, Reuter SR. Trauma of the extremities: prospective comparison of digital and conventional angiography. *Radiology*. 1986;160:179–182.
- O’Gorman RB, Feliciano DV, Bitondo CG, Mattox KL, Burch JM, Jordan GL Jr. Emergency center arteriography in the evaluation of suspected peripheral vascular injuries. *Arch Surg*. 1984;199:568–573.
- Morozumi J, Ohata S, Homma H, et al. Introduction of mobile angiography into the trauma resuscitation room. *J Trauma*. 2009;67:245–251.
- Itani KMF, Burch JM, Spjut-Patrinely V, Richardson R, Martin RR, Mattox KL. Emergency center arteriography. *J Trauma*. 1992;32:302–307.
- Inaba K, Potzman J, Munera F, et al. Multi-slice CT angiography for arterial evaluation in the injured lower extremity. *J Trauma*. 2006;60:502–507.
- Rieger M, Mallouhi A, Tauscher T, Lutz M, Jaschke WR. Traumatic arterial injuries of the extremities: initial evaluation with MDCT angiography. *Am J Roentgenol*. 2006;186:656–664.

49. Fleiter TR, Mervis S. The role of 3D-CTA in the assessment of peripheral vascular lesions in trauma patients. *Eur J Radiol.* 2007;64:92–102.
50. Seamon MJ, Smoger D, Torres DM, et al. A prospective validation of a current practice: the detection of extremity vascular injury with CT angiography. *J Trauma.* 2009;67:238–244.
51. White PW, Gillespie DL, Fuerstein I, et al. Sixty-four slice multidetector computed tomographic angiography in the evaluation of vascular trauma. *J Trauma.* 2010;68:96–102.
52. Lynch TG, Hobson RW II. Noninvasive cerebrovascular diagnostic techniques. In: Hobson RW II, Wilson SE, Veith FJ, eds. *Vascular Surgery. Principles and Practice.* 3rd ed., Revised and Expanded. New York, NY: Marcel Dekker, Inc.; 2004:123–152.
53. Bynoe RP, Miles WS, Bell RM, et al. Noninvasive diagnosis of vascular trauma by duplex ultrasonography. *J Vasc Surg.* 1991;14:346–352.
54. Fry WR, Smith RS, Sayers DV, et al. The success of duplex ultrasonographic scanning in the diagnosis of extremity vascular proximity trauma. *Arch Surg.* 1993;128:1368–1372.
55. Gagne PJ, Cone JB, McFarland D, et al. Proximity penetrating extremity trauma: the role of duplex ultrasound in the detection of occult venous injuries. *J Trauma.* 1995;39:1157–1163.
56. Bergstein JM, Blair JF, Edwards J, et al. Pitfalls in the use of color-flow duplex ultrasound in penetrated extremities. *J Trauma.* 1992;33:395–402.
57. Stain SC, Yellin AE, Weaver FA, et al. Selective management of nonocclusive arterial lesions. *Arch Surg.* 1989;124:1136–1141.
58. Dente CJ, Wyrzykowski AD, Feliciano DV. Fasciotomy. *Curr Prob Surg.* 2009;46:769–840.
59. Ingegno MD, Williams RA. Pentoxifylline, vasodilators, and metabolic agents. In: Veith FJ, Hobson RW, Williams RA, Wilson SE, eds. *Vascular Surgery. Principles and Practice.* 2nd ed. New York, NY: McGraw-Hill, Inc; 1994:242–245.
60. Dickerman RM, Gewertz BL, Foley DW, Fry WJ. Selective intra-arterial tolazoline infusion in peripheral arterial trauma. *Surgery.* 1977;81:605–609.
61. Peck JJ, Fitzgibbons TJ, Gaspar MR. Devastating distal arterial trauma and continuous infusion of tolazoline. *Am J Surg.* 1983;145:562–566.